

# WORLD JOURNAL OF GASTROENTEROLOGY, HEPATOLOGY AND ENDOSCOPY



## Esophageal bezoar on peptic stenosis in a 7-year-old child

Bakkali O\*, Meskini T,  
Berrani H, Sabib M,  
Ettair S and Mouane N

Department of Pediatric Hepatology Gastroenterology and Nutrition, Rabat Children's Hospital, Morocco

### Article Information

**Article Type:** Case Report

**Journal Type:** Open Access

**Volume:** 3 Issue: 6

**Manuscript ID:** WJGHE-3-144

**Publisher:** Science World Publishing

**Received Date:** 10 Oct 2021

**Accepted Date:** 16 Oct 2021

**Published Date:** 22 Oct 2021

**\*Corresponding Author:**

**Oujid Bakkali,**

Department of Pediatric Hepatology  
Gastroenterology and Nutrition, Rabat  
Children's Hospital, Morocco,  
Tel: +212623723317;  
E-mail: doctor.bakkali@gmail.com

**Citation:**

Bakkali O. (2021). Esophageal bezoar on peptic stenosis in a 7-year-old child. World J Gastroenterol Hepatol Endosc. 3(6); 1-3

**Copyright:** © 2021, Bakkali O, *et al.*, This is an open-access article distributed under the terms of the Creative Commons Attribution 4.0 international License, which permits unrestricted use, distribution and reproduction in any medium, provided the original author and source are credited.

### ABSTRACT

The term bezoar refers to foreign bodies found in the digestive tract. It results in a stagnation of ingested non-digestible substances. We report a case of an esophageal bezoar collected in the pediatric gastroenterology department of the children's hospital in Rabat- MOROCCO. This observation of an esophageal bezoar, the first in our institution, to our knowledge, confirms the rarity of the pathology. 7-year-old child, taken by his parents to the children's hospital of the university hospital in Rabat for total aphagia. His history shows: psychomotor retardation, followed for 2 years for peptic esophagitis complicated by peptic stenosis. The course was marked by total aphagia, early postprandial vomiting, and weight loss of 6 kg in 3 months. This symptomatology has been evolving for 2 months. Esophagogastroduodenal fibroscopy, using an 8.5mm pediatric fiberscope, revealed an esophageal bezoar made of tissues, fibers, hair, sponge, plastics and ropes. A multistage endoscopic extraction was performed, which extracted a 430g bezoar. After a complete cleansing of the esophagus, the esophagogastroduodenal exploration showed ascension of the gastric folds on retrovision, a gaping cardia, a hernial pouch, an esophageal caliber disparity of 25 cm to 20 cm of the dental arches with presence of mucous ulcerations and false membranes. After extraction, the child resumed his normal diet with no vomiting. a proton pump inhibitor and antibiotic therapy were prescribed.

### INTRODUCTION

The term bezoar refers to foreign bodies found in the digestive tract. It results in a stagnation of ingested non-digestible substances, such as hair (trichobezoar), certain vegetable fibers (phytobezoar), concentrated dairy products (lactobezoar), more rarely certain drugs (pharmacobezoar). Its esophageal location is little reported in the literature, it is often secondary to a morphological and / or functional abnormality of the esophagus and is frequently involved. It usually concerns children or young adolescents with mental disorders [1]. We report a case of an esophageal bezoar collected in the pediatric gastroenterology department of the children's hospital in Rabat- MOROCCO. This observation of an esophageal bezoar, the first in our institution, to our knowledge, confirms the rarity of the pathology.

### PATIENT AND OBSERVATION

7-year-old child, taken by his parents to the children's hospital of the university hospital in Rabat for total aphagia. His history shows: psychomotor retardation, followed for 2 years for peptic esophagitis complicated by peptic stenosis. The course was marked by total aphagia, early postprandial vomiting, and weight loss of 6 kg in 3 months. This symptomatology has been evolving for 2 months. The admission exam noted: a pale patient. A weight of 12kg (- 3 DS), a height of 114cm (- 2DS).

The biological assessment showed on the blood count: Hemoglobin at 6.3 g / dL with erythrocyte indices in favor of microcytic hypochromic anemia, leukocytes at 15200 / mm<sup>3</sup>, polymorphonuclear cells at 12200 / mm<sup>3</sup>, lymphocytes at 2000 / mm<sup>3</sup>. Blood sugar and CRP were within standards.

Esophagogastroduodenal fibroscopy, using an 8.5mm pediatric fiberscope, revealed an esophageal bezoar made of tissues, fibers, hair, sponge, plastics and ropes (Figure 1). A multistage endoscopic extraction was performed, which extracted a 430g bezoar

(Figure 2). After a complete cleansing of the esophagus, the esophagogastroduodenal exploration showed an ascension of the gastric folds on retrovision (Figure 3), a gaping cardia, a hernial pouch, an esophageal caliber disparity of 25 cm to 20 cm of the dental arches with presence of mucous ulcerations and false membranes (Figure 4).

After extraction, the child resumed his normal diet with no vomiting. a proton pump inhibitor and antibiotic therapy were prescribed.

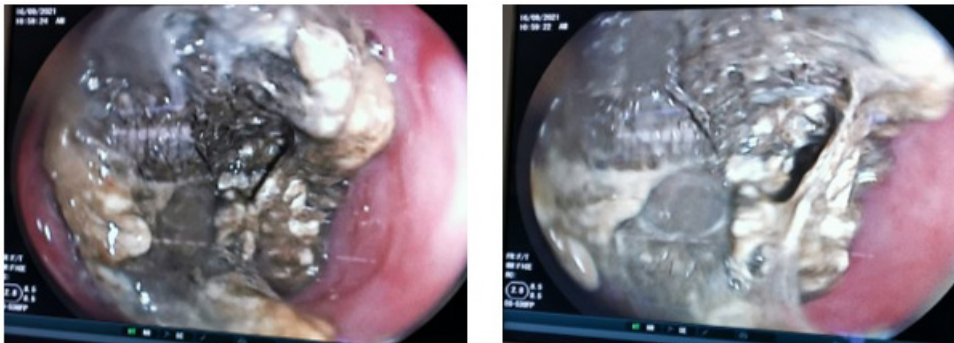

Figure 1: Endoscopic images of an esophageal bezoar.

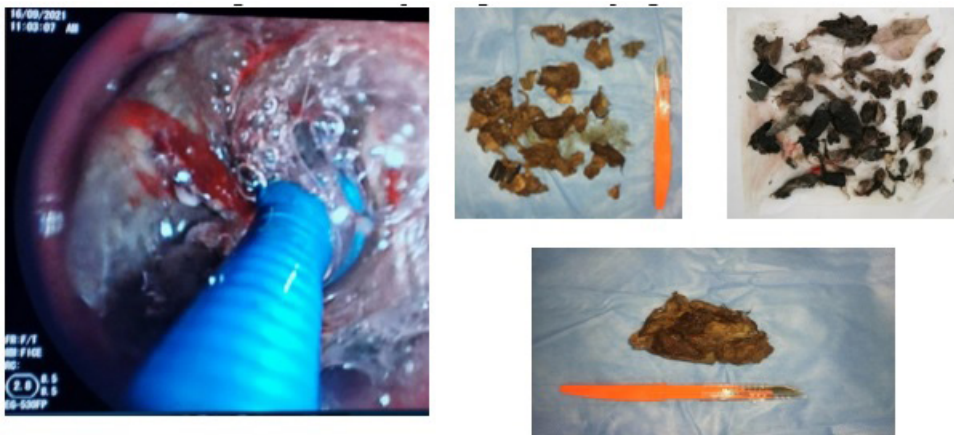

Figure 2: Endoscopic bezoar extraction

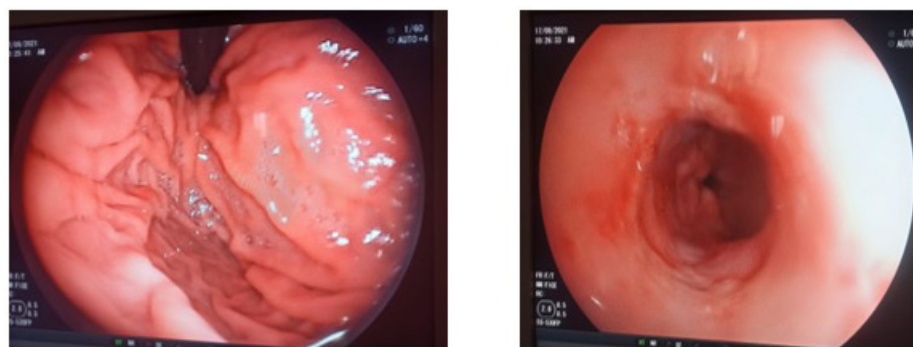
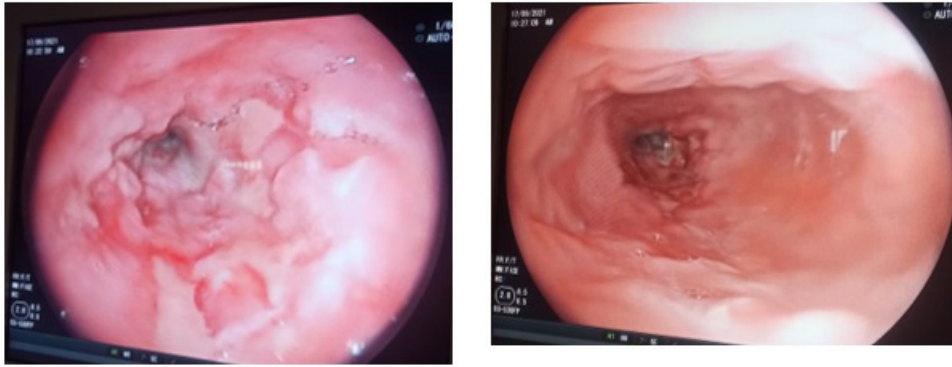


Figure 3: Endoscopic image showing an ascending gastric folds, a gaping cardia and a hernial pouch.



**Figure 4:** Endoscopic image of esophagitis with esophageal peptic stenosis.

## DISCUSSION

The bezoar a rare affection in children, it represents 0.15% of gastrointestinal foreign bodies. Gastric localization is the most frequent. The particularity of our case is above all the esophageal location, which is often unusual and unrecognized. Psychomotor retardation is often seen in patients followed for psychological pathologies, in our case. [2].

Esophageal bezoars can be divided into two groups: primary which occur in the esophagus and secondary where gastric bezoars migrate to the esophagus [3]. cases of esophageal bezoars which have been reported in patients with a functional and / or morphological abnormality of the esophagus (systemic disease, hypertonia of the lower esophageal sphincter, myasthenia gravis, Guillain-Barre syndrome, diabetes, diffuse spasm disease, achalasia, surgery of the esophagus, stomach, peristalsis syndrome ...) [4, 6]. Our case is one of the few primary esophageal bezoars reported in the literature that caused peptic esophageal stenosis, resulting in vomiting and total aphagia.

The esophageal bezoar is manifested by swallowing disorders (dysphagia). It is rarely revealed by dyspnea [7]. In our observation, the patient reported mainly aphagia, vomiting and weight loss.

Once the diagnosis of esophageal bezoar is clinically evoked, it is necessary to confirm it by endoscopy, which remains the examination of choice in cases of proximal esogastric and intestinal location. It has both diagnostic and therapeutic interests.

In our case, the lumen of the esophagus is narrow and the risk of aspiration of fragments during the procedure makes bezoars difficult to treat. Thus, it is more convenient to break up the bezoar into fragments in the stomach by overtube-assisted endoscopy for an esophageal bezoar when possible. Broken bezoar particles can be extracted or pushed into the small intestine. However, intestinal obstruction can occur if the large fragments migrate into the small intestine.

Conservative medical treatment can be used in front of small bezoars. Coca-Cola washes and endoscopic procedures can be used with a success rate of 91.3% has been reported in the treatment of gastric bezoars [8]. However, larger bezoars, endoscopic intervention or even surgery may be necessary.

## CONCLUSION

The bezoar is a disease rarely seen in children. Its location in the esophagus is unusual. It is favored by functional or motor disorders of the esophagus with multiple etiologies. Gastrointestinal endoscopy remains the examination of choice. Endoscopic or even surgical treatment significantly improves symptoms.

## Reference

1. L'aarje A, Elhattabi K, Lefryekh R, Fadil A, Khaiz D, Berrada S, et al., Trichobézoard gastroduodéal et grélique. *Presse Med.* 2016; 45: 265-9.
2. Ziadi T, En-nafaa I, Lamsiah T, Abilkacem EH, Hanine A, Hoummadi A. Une masse épigas-trique. *Rev Med Interne.* 2011; 32: 445-6.
3. Chaudhry I, Asban A, Kazoun R, Khurshid I. Lithobezoar, a rare cause of acute oesophageal obstruction: surgery after failure of endoscopic removal. *BMJ case rep.* 2013; 2013: bcr2013008984.
4. Chen YC, Tsai MC, Chen TY, Lin CC. Esophageal bezoar in a patient with esophageal epiphrenic diverticulum. *Endoscopy.* 2013; 45: E193-4.
5. Goel AK, Seenu V, Srikrishna NV, Goyal S, Thakur KK, Shukla NK. Esophageal bezoar: a rare but distinct clinical entity. *Trop. Gastroenterol.* 1995; 16: 43-7.
6. Kim KH, Choi SC, Seo GS, Kim YS, Choi CS, Im CJ. Esophageal bezoar in a patient with achalasia: case report and literature review. *Gut. Liver.* 2010; 4: 106-9.
7. Metman EH, Debbabi S, Negreanu L. Troubles moteurs de l'oesophage. *EMC, Gastro-entérologie.* 2006; 1: 1-19.
8. Ladas SD, Kamberoglou D, Karamanolis G, Vlachogiannakos J, Zouboulis-Vafiadis I. Systematic review: Coca-Cola can effectively dissolve gastric phytobezoars as a first-line treatment. *Aliment. Pharmacol. Ther.* 2013; 37: 169-73.